

Actinomyces Odontolyticus with *Klebsiella* and *Bacteroides* Presenting as Facio-Cervical Abscess with Extension to Scalp and no Sinus Tract

¹Tanveer Mir, ¹Anita Choudhary, ¹Anshu Wadehra, ¹Pragnesh Patel and ²Sabah Ambreen

¹Department of Internal Medicine DMC/Wayne State University Michigan, USA

²Detroit Michigan USA

Article history

Received: 17-01-2019

Revised: 28-05-2019

Accepted: 11-06-2019

Corresponding Author:

Tanveer Mir

Department of Internal
Medicine DMC/Wayne State
University Michigan, USA
Email: drtms907@gmail.com

Abstract: Actinomycosis is a rare infectious bacterial disease caused by various *Actinomyces* species. Being very rare, *Actinomyces* is easily misdiagnosed. *Actinomyces* are common commensals of the oral cavity which predispose to local infections. We report a case of a 67-year-old female who initially presented with swelling of the left sided face which later on proved to be a mixed infection with actinomycosis. CT imaging of head and neck was done, which revealed an abscess over the cervicofacial region. The abscess was drained and the pus was cultured in aerobic and anaerobic medium. Cultures grew actinomycosis with superadded *Bacteroides* and *Klebsiella*. The patient was managed with incision and drainage, as well as ceftriaxone. Actinomycosis is a rare infection in cervicofacial region, however, we should keep our differentials open always. Both clinical and microbiological diagnosis avoids serious errors in diagnosis.

Keywords: Actinomycosis, Facial Abscess, Mixed Abscess

Introduction

Actinomycosis is a bacterial infection. Actinomycosis can affect any part of body especially soft tissue and mainly involving in the cervicofacial region leading to abscess formation (Jameson *et al.*, 2018). Involvement in cervicofacial region leads to abscess formation and can lead to osteomyelitis of mandible (Jameson *et al.*, 2018; Sharkawy and Chow, 2019). Our patient had an abscess in the temporal and parotid region extending to left submandibular region. As Actinomycosis is a rare disease and since our patient had an abscess which encompassed the left temporal, parotid and submandibular regions, we report this case to highlight non-lymphatic regional spread.

Case Report

A 67 years old African American female with no previous medical conditions presented with left side facial swelling, which was progressive and painful. The patient reported that all of this started after she had pain in her left lower molar tooth.

On examination, patient had stable vital signs, including no febrile episodes. She had edema of the left-sided face with a fluctuant swelling in the left temporal region, as well as an indurated swelling at the left parotid region extending to the submandibular region. The rest of the general and

systemic examination was unremarkable. Labs revealed a neutrophilic leukocytosis with normocytic, normochromic anemia, likely anemia of chronic disease secondary to the abscess. Blood glucose, BUN/CRT and liver function tests were normal. HIV screening (antigen/antibody testing) was negative. CT scan of the head and neck was obtained, which revealed a large abscess with surrounding cellulitis involving the left sided scalp and soft tissues of the neck/maxillofacial region. There was a thin communication between the scalp fluid collection and maxillofacial fluid collection anteriorly along the zygomatic arch. The cranial portion of the fluid collection measured 8.5×8.2×2.1 cm in the A-P orientation, extending from the mid parietal region to the skull base. Mild adenopathy in posterior triangle was present as shown in Fig. 1a and 1b.

Incision and drainage was performed and fluid grew *Klebsiella Pneumoniae* in aerobic cultures, which were sensitive to ceftriaxone. *Actinomyces Odontolyticus* and *Bacteroides* grew in the anaerobic culture media after 7 days of incubation and was sensitive to ceftriaxone. The patient was managed with flagyl for *Bacteroides* and ceftriaxone for *Klebsiella* and *Actinomyces*. During her treatment, her white blood cell count improved and her hemoglobin improved with good response in her reticulocyte count. Patient was scheduled to follow-up with an Infectious Disease specialist as an outpatient to complete treatment for a total of 6 months.

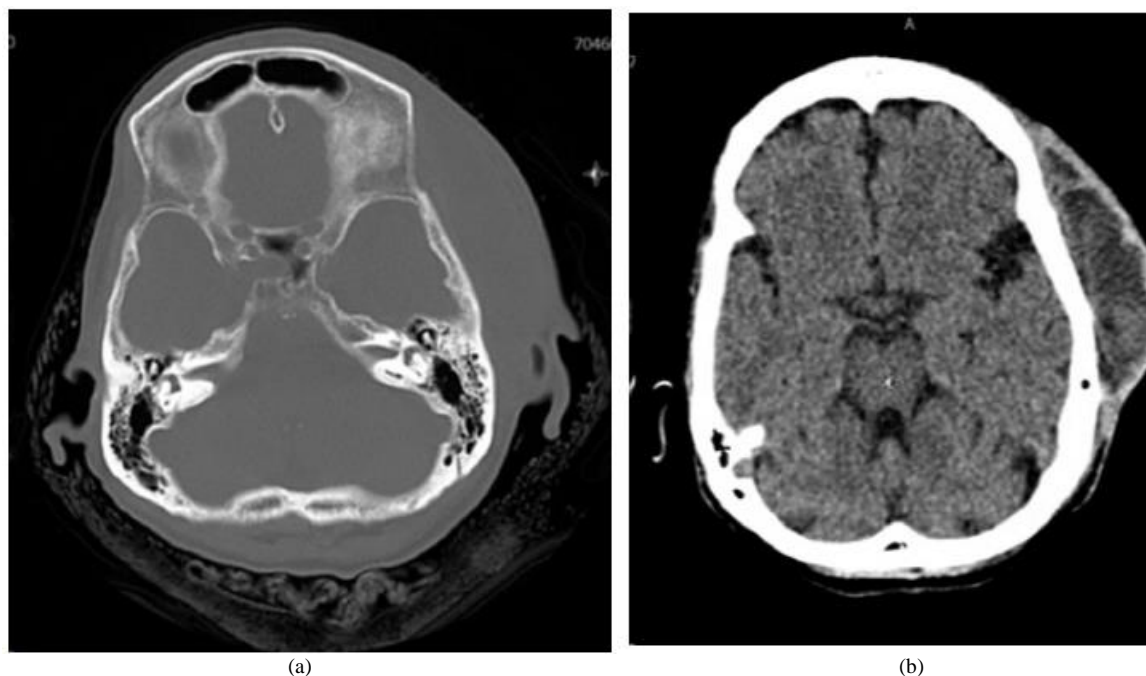


Fig. 1: Cervicofacial abscess in a case of actinomycosis. Patient has abscess in temporoparietal region

Discussion

Actinomycosis is a rare disease in the United States (Jameson *et al.*, 2018; Volante *et al.*, 2005; Smego and Foglia, 1998). Actinomyces are gram-positive, non-acid fast, anaerobic or microaerophilic filamentous branched bacteria which colonize the mouth, colon and vagina. They form normal commensals of oral cavity. Mucosal disruption can lead to infection in virtually any part of the body (Jameson *et al.*, 2018). Actinomyces are very difficult to grow in culture, with less than 30% of cultures being positive (Volante *et al.*, 2005). Most common Actinomyces isolated is *A. Israelii*, *A. Propionica*, *A. Naeslundii*, *A. Viscosus* and *A. Odontolyticus* which can lead to infections (Jameson *et al.*, 2018).

Infection in Cervicofacial region is the most common manifestation of actinomycosis reported in literature, while involvement of central nervous system, thoracic, abdominal and pelvic actinomycosis occur less frequently (Kwartler, and Limaye, 1989; Könönen and Wade, 2015; Sharkawy and Chow, 2019). Dental procedures or having dental caries puts a patient at a high risk of cervicofacial involvement (Könönen and Wade, 2015).

Symptoms are often non-specific like in our patient. They most of the times complain of tightness, otherwise pain is rare. Patients can present with fever at the beginning especially when superadded infections are present (Könönen and Wade, 2015; Brown, 1973). Our patient presented with a swelling in the cervicofacial

region with a tension from the swelling, which is most common presentation. The swelling and tension increase progressively (Jameson *et al.*, 2018; Sharkawy and Chow, 2019; Brown, 1973). In the cervicofacial region a fluctuant swelling is noticed most commonly around the mandible which can extend further (Belmont *et al.*, 1999).

In microbiology, final diagnosis, as with other microorganisms, depends upon culture. For making a final diagnosis it is important to isolate the bacteria in culture. Actinomyces generally grow in aerobic microaerophilic culture (Jameson *et al.*, 2018). Growth of the microorganism is very difficult and less often do we see the growth (Yadav *et al.*, 2002).

Tissue biopsy can also help in diagnosis especially as culture is difficult. Taking multiple sections from the lesion at different levels enhances chances of diagnosis (Lerner, 1988). Biopsy typically reveals acute or chronic inflammatory granulation tissue with infiltration by neutrophils, foamy macrophages, plasma cells and lymphocytes. Sulfur granules may be present (Jameson *et al.*, 2018; Sharkawy and Chow, 2019).

Management of cervicofacial actinomycosis requires a prolonged course of antibiotics. High-dose penicillin is the treatment of choice for actinomycosis (Smego and Foglia, 1998). Surgical excision and drainage of the abscess can help in management especially if the abscess is extensive (Bennhoff, 1984).

In our patient we did not suspect actinomycosis initially because the primary abscess was over the temporal region, extending behind ear and there was no draining sinus. Diagnosis was confirmed once cultures

came back positive after seven days. The main aim of reporting this case is that one should keep the differential of a cervicofacial abscess broad and to include actinomycosis as a potential diagnosis, even if it is very rare. As the treatment for actinomycosis is for a prolonged duration, it is imperative that providers be vigilant in their diagnosis. If inadequately treated, actinomycosis can lead to serious complications.

Conclusion

In conclusion, although it is a rare infection, actinomycosis of the head and neck represents an important diagnosis which should not be missed. Both clinical and microbiological diagnosis avoids serious errors in diagnosis.

Acknowledgement

Department of Internal Medicine, Detroit Medical Center/Wayne State University.

Author's Contributions

Tanveer Mir: Design, data collection, revised manuscript.

Anita Choudhary and Anshu Wadehra: Contributed to designing, collection of data, revised article. I gave final approval.

Pragnesh Patel: Design and data collection.

Sabah Ambreen: Design and revised manuscript.

Ethics

There was no animal involved in this report. We got verbal consent from the patient. We are not disclosing identity of the patient.

References

Belmont, M.J., P.M. Behar and M.K. Wax, 1999. Atypical presentations of actinomycosis. *Head Neck*, 21: 264-268.
DOI: 10.1002/(SICI)1097-0347(199905)21.3.264

Bennhoff, D.F., 1984. Actinomycosis: Diagnostic and therapeutic considerations and a review of 32 cases. *Laryngoscope*, 94: 1198-1198.
DOI: 10.1288/00005537-198409000-00013

Brown, J.R., 1973. Human actinomycosis a study of 181 subjects. *Hum. Pathol.*, 4: 319-330.
DOI: 10.1016/S0046-8177(73)80097-8

Jameson, J.L., A.S. Fauci, D.L. Kasper, S.L. Hauser and D.L. Longo *et al.*, 2018. Harrison's Principles of Internal Medicine. In: Actinomycosis, Thomas, A.R. (Ed.), McGraw-Hill Education, ISBN-10: 1259644030, pp: 1220-1223.

Könönen, E. and W.G. Wade, 2015. Actinomyces and related organisms in human infections. *Clin. Microbiol. Rev.*, 28: 419-419.
DOI: 10.1128/CMR.00100-14

Kwartler, J.A. and A. Limaye, 1989. Pathologic quiz case 1 cervicofacial actinomycosis. *Arch Otolaryngol Head Neck Surg.*, 115: 524-524.

Lerner, P.I., 1988. The lumpy jaw Cervicofacial actinomycosis. *Infect. Dis. Clin. North Am.*, 2: 203-203.

Sharkawy, A.A. and A.W. Chow, 2019. Uptodate.com. Smego, R.A.J. and G. Foglia, 1998. Actinomycosis. *Clin Infect. Dis.*, 26: 1255-1261. DOI: 10.1086/516337

Volante, M., A.M. Contucci, M. Fantoni R. Ricci and J. Galli, 2005. Cervicofacial actinomycosis: Still a difficult differential diagnosis. *Acta Otorhinolaryngol Ital.*, 25: 116-119.
PMID: 16116835

Yadav, S.P., R. Chanda, G. Gathwala and R.K. Yadav, 2002. Actinomycosis of tonsil masquerading as tumour in a 12-year-old child. *Int. J. Pediatr. Otorhinolaryng.*, 63: 73-75.
DOI: 10.1016/S0165-5876(01)0064